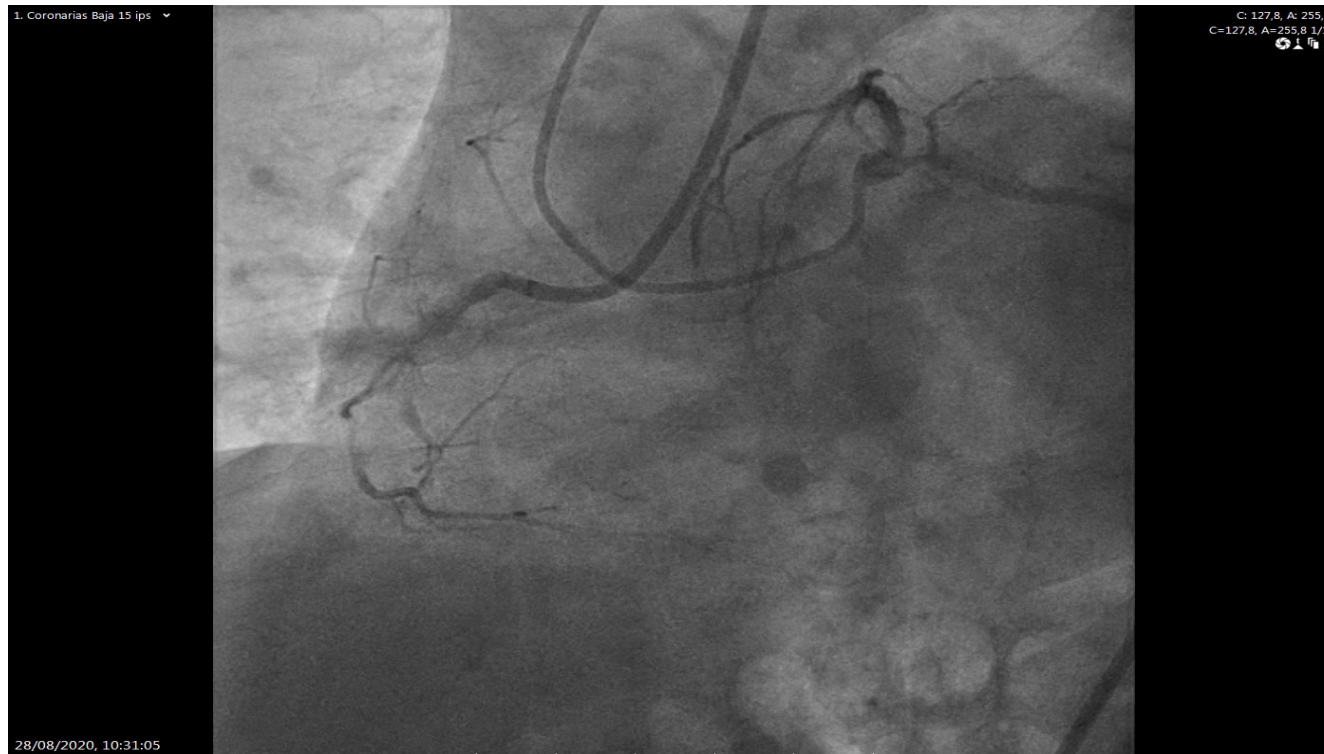

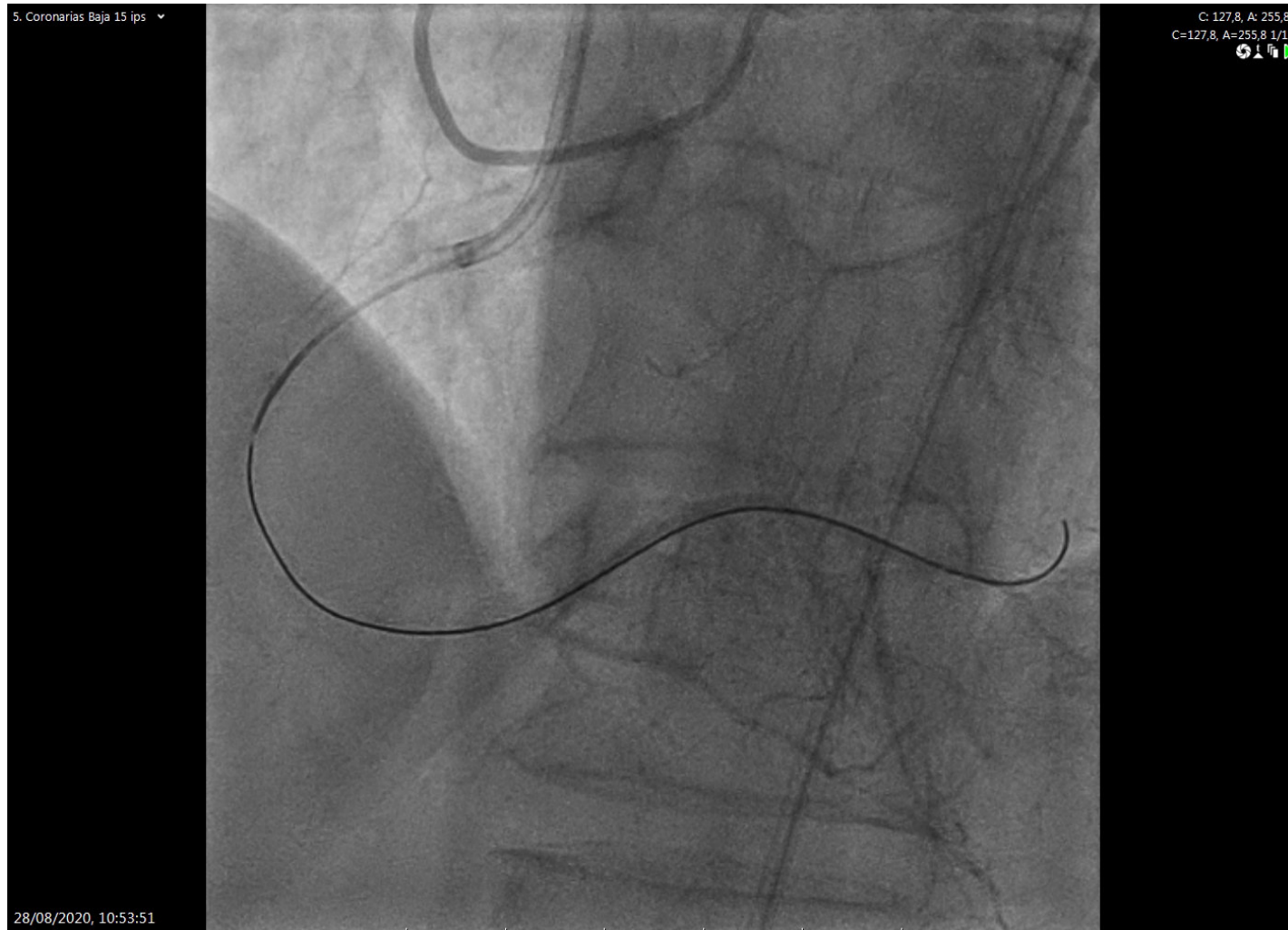
BIOFREEDOM EN OCT

Paciente de 78 años
Fibrilacion auricular cronica
ACO
Angina de esfuerzo GF III/IV
Isquemia inferolateral

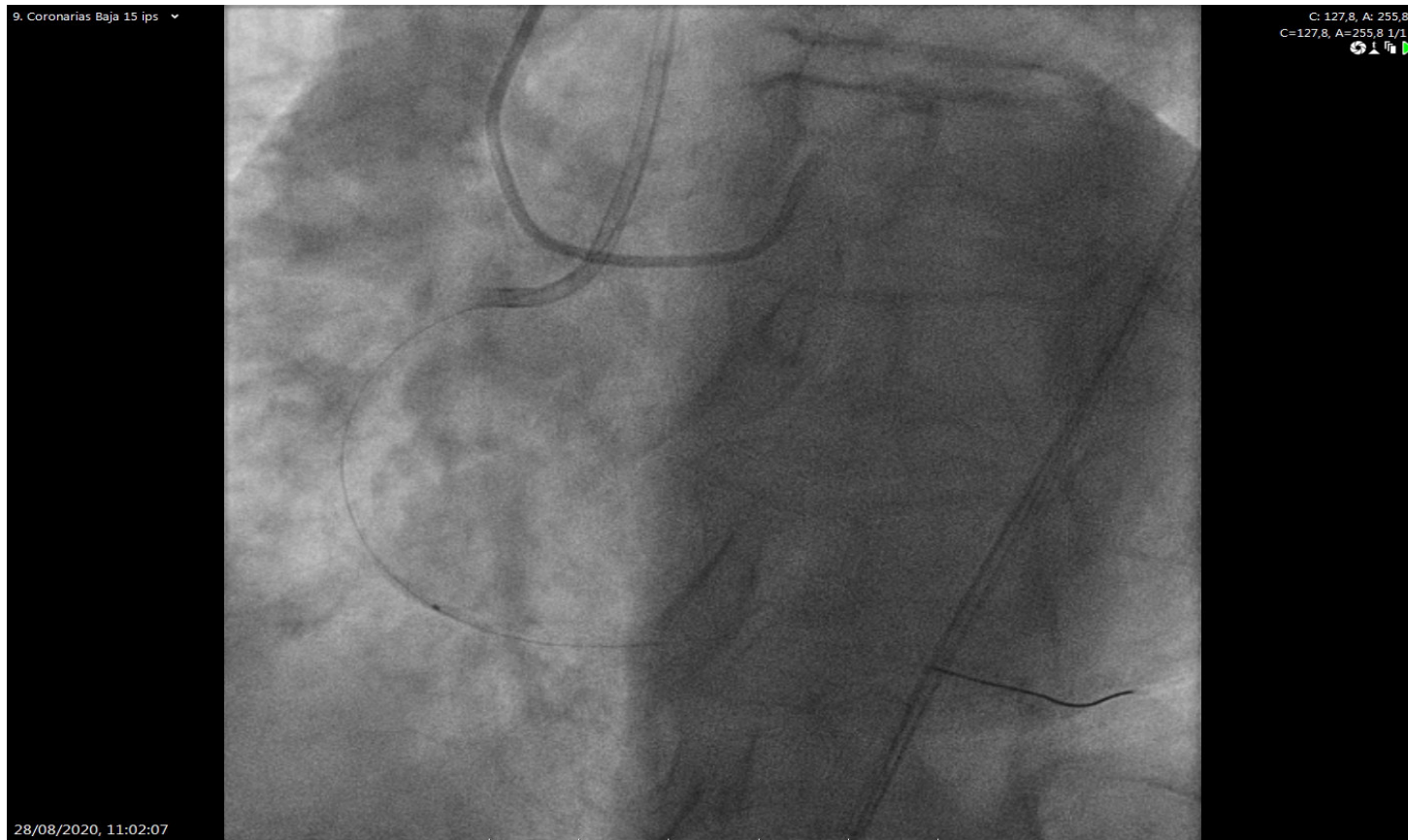
OCT DE CD



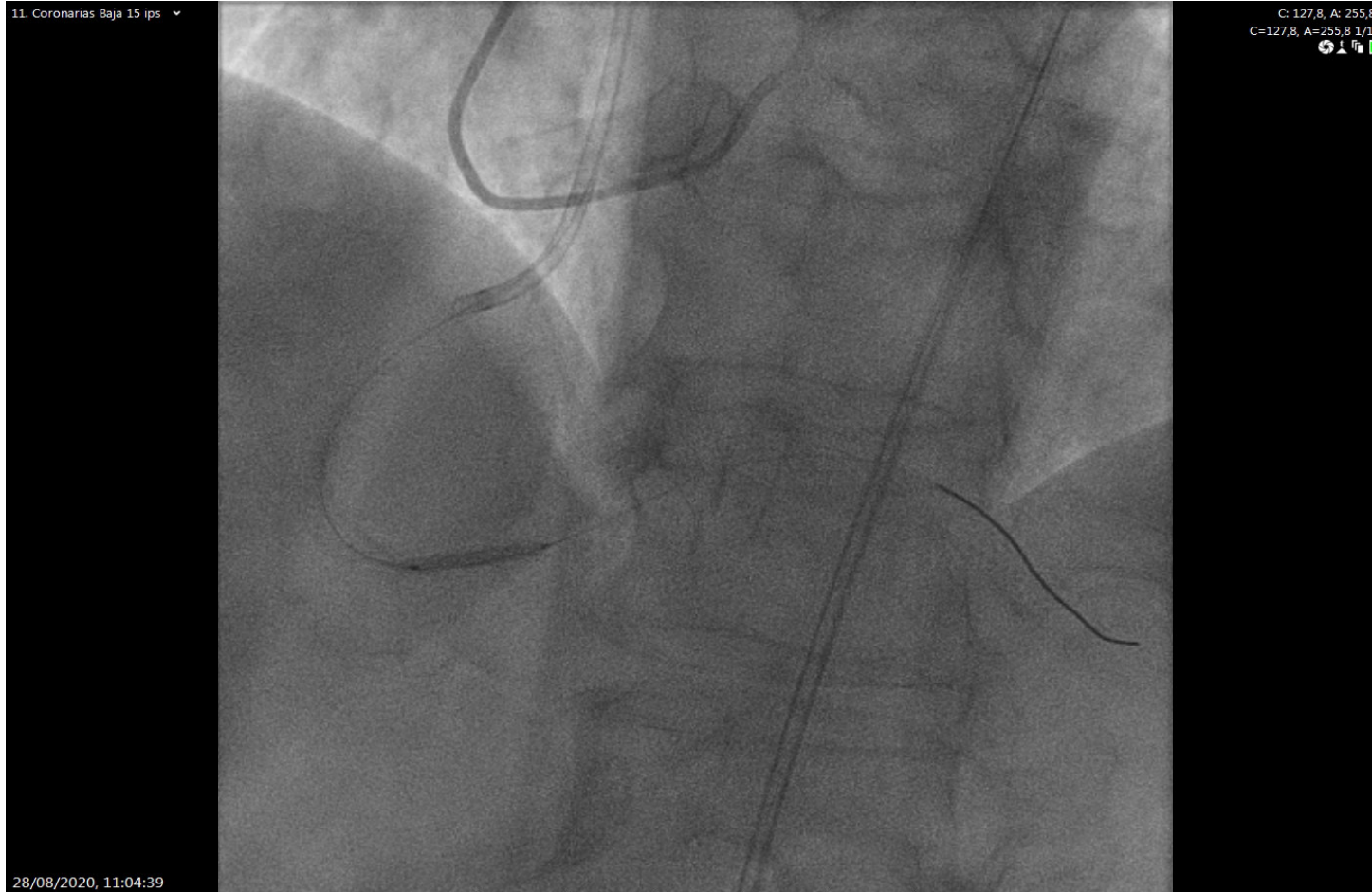
MICROCATETER Y GUIA ULTIMATE 3



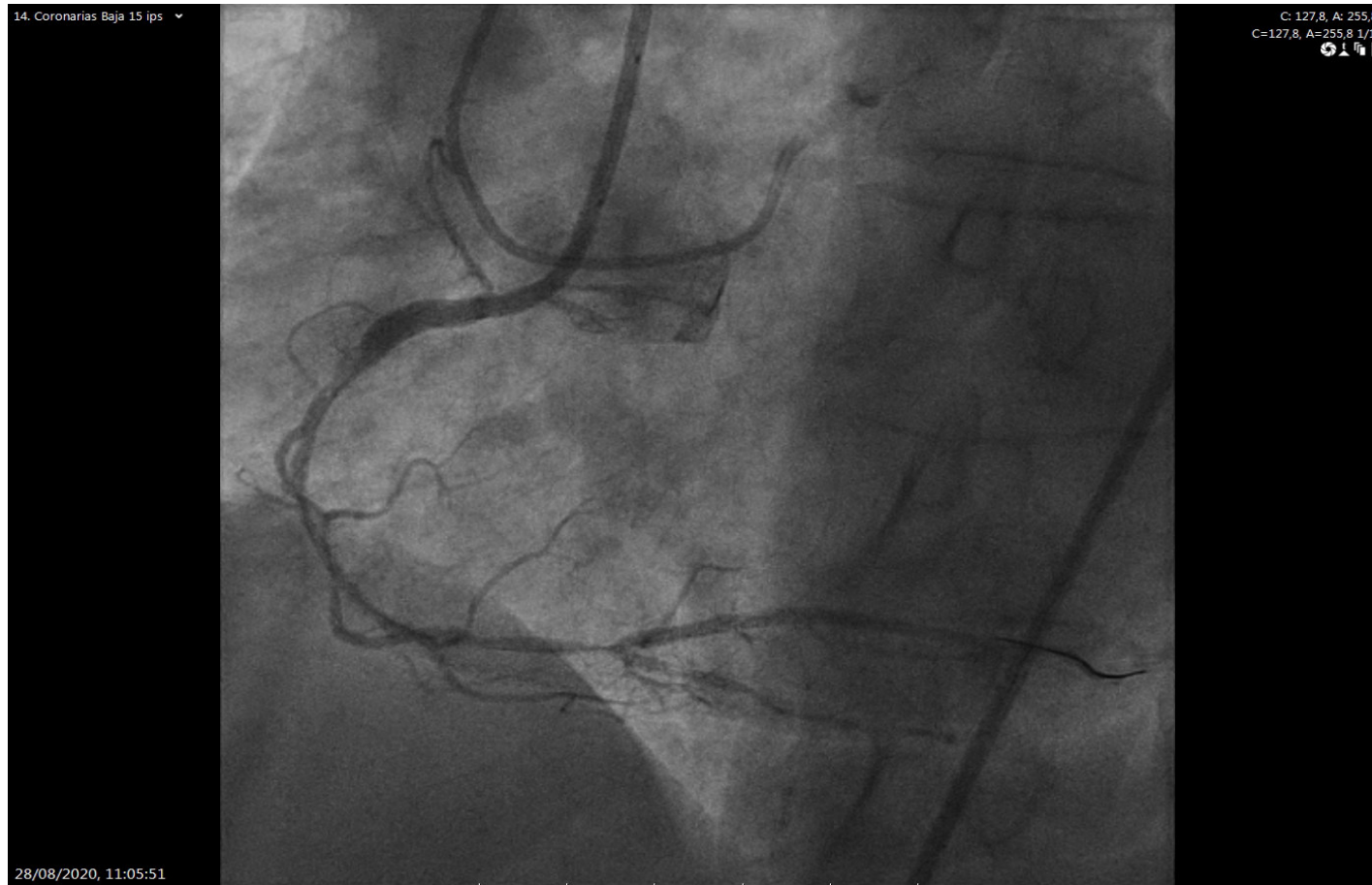
BALON DE 1,5



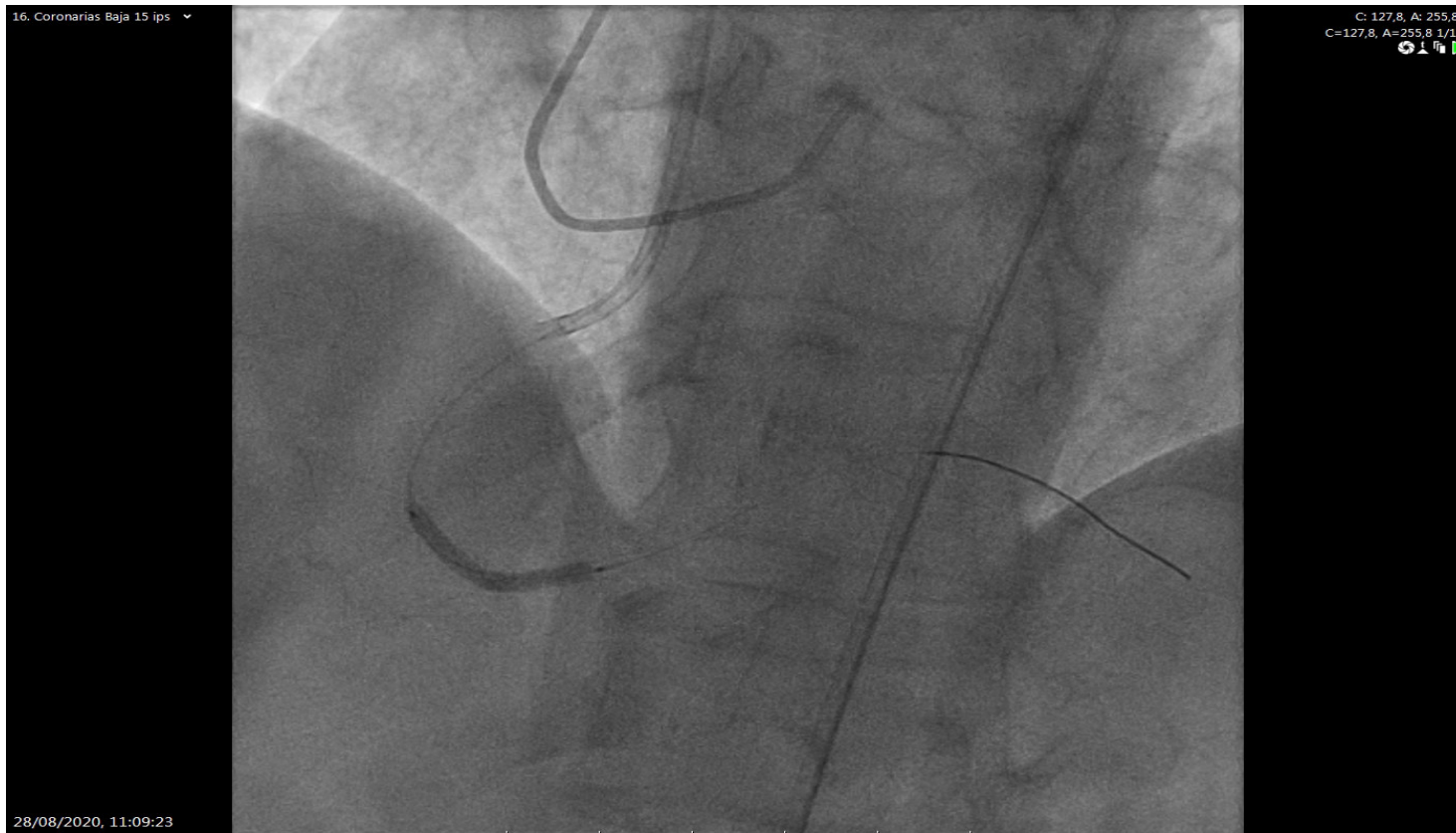
BALON DE 2



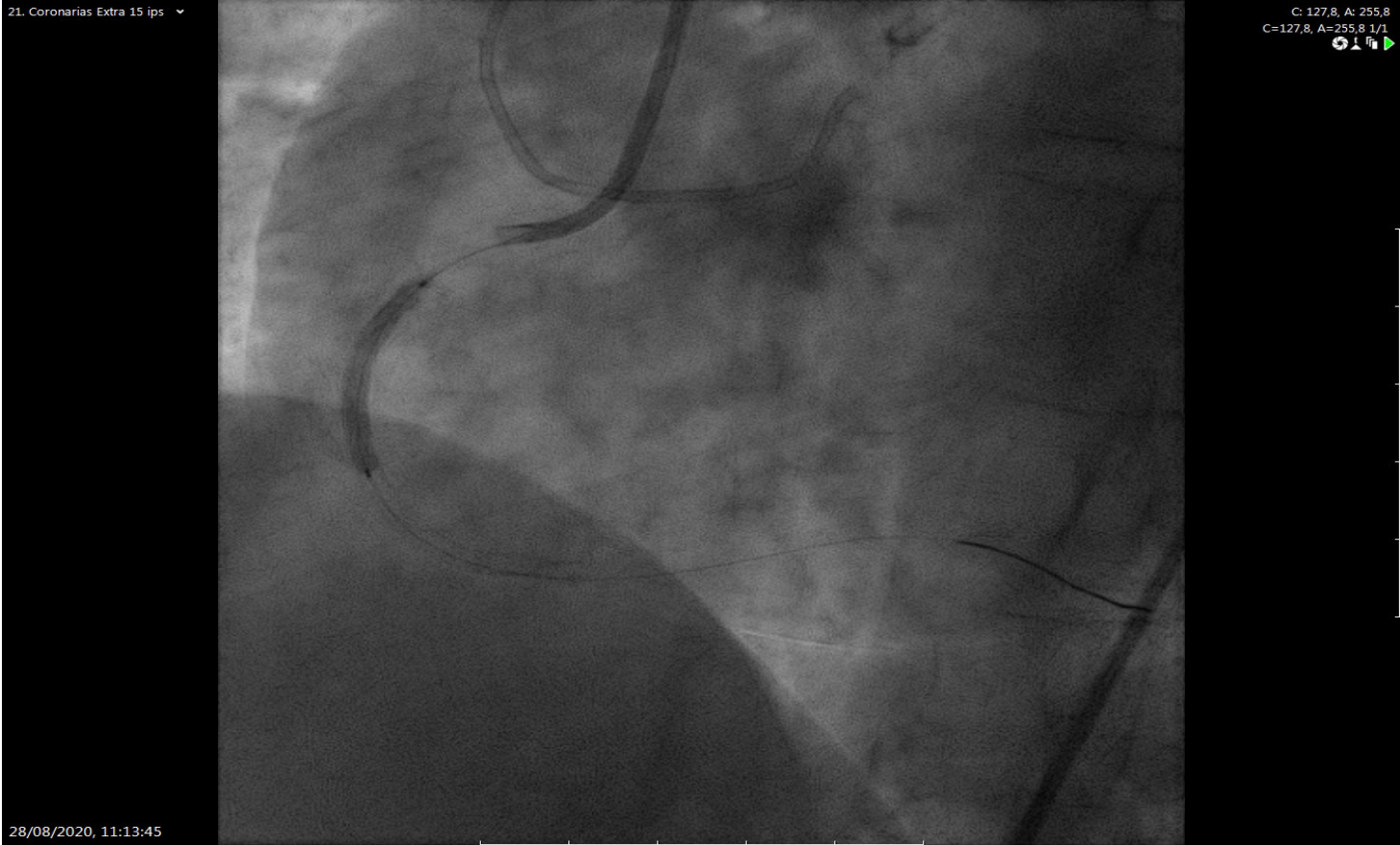
DESPUES DE ACTP



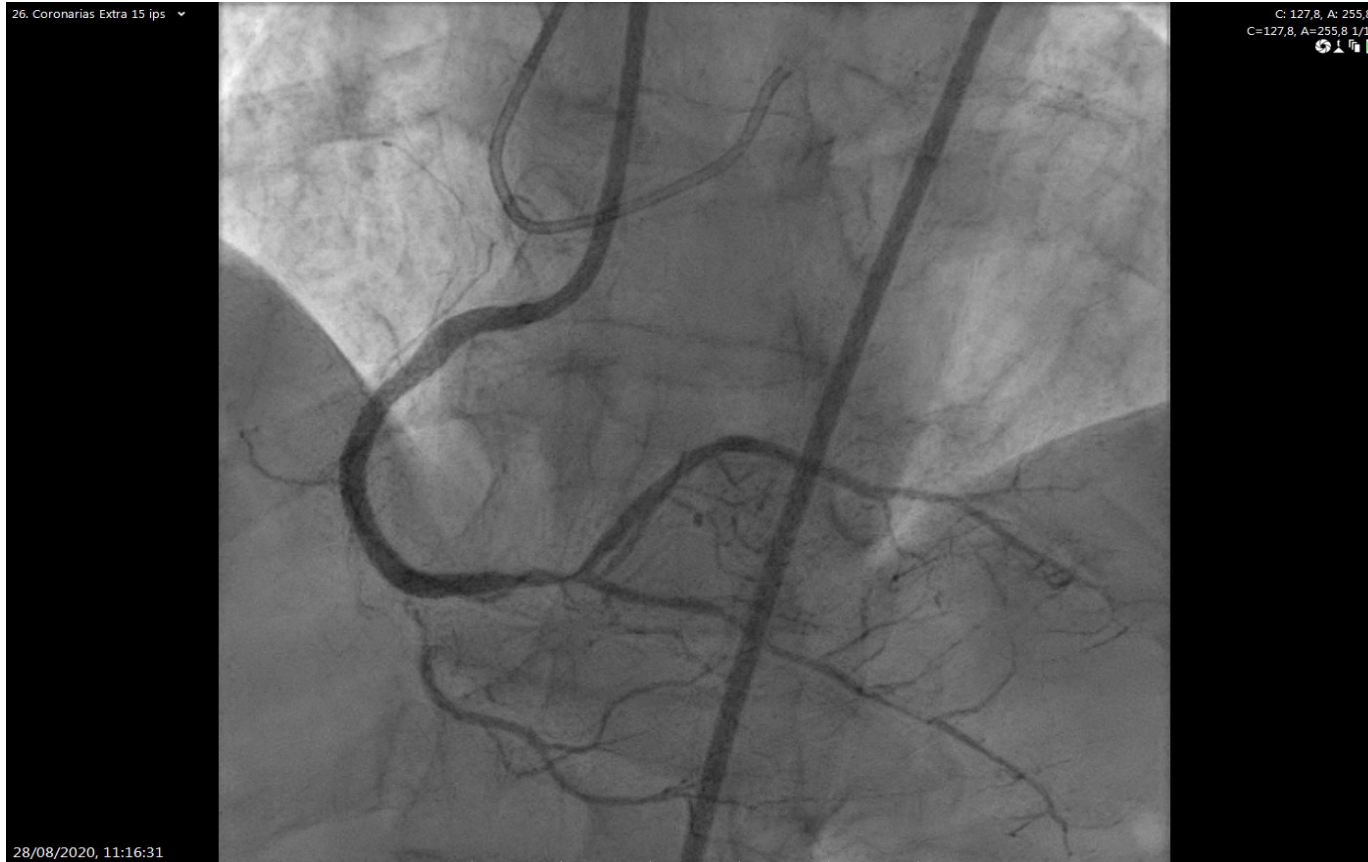STENT BIOFREEDOM 2,5 X 33



STENT BIOFEEDOM 3 X 24



RESULTADO FINAL



STENT DIRECTO BIOFREEDOM EN SCA

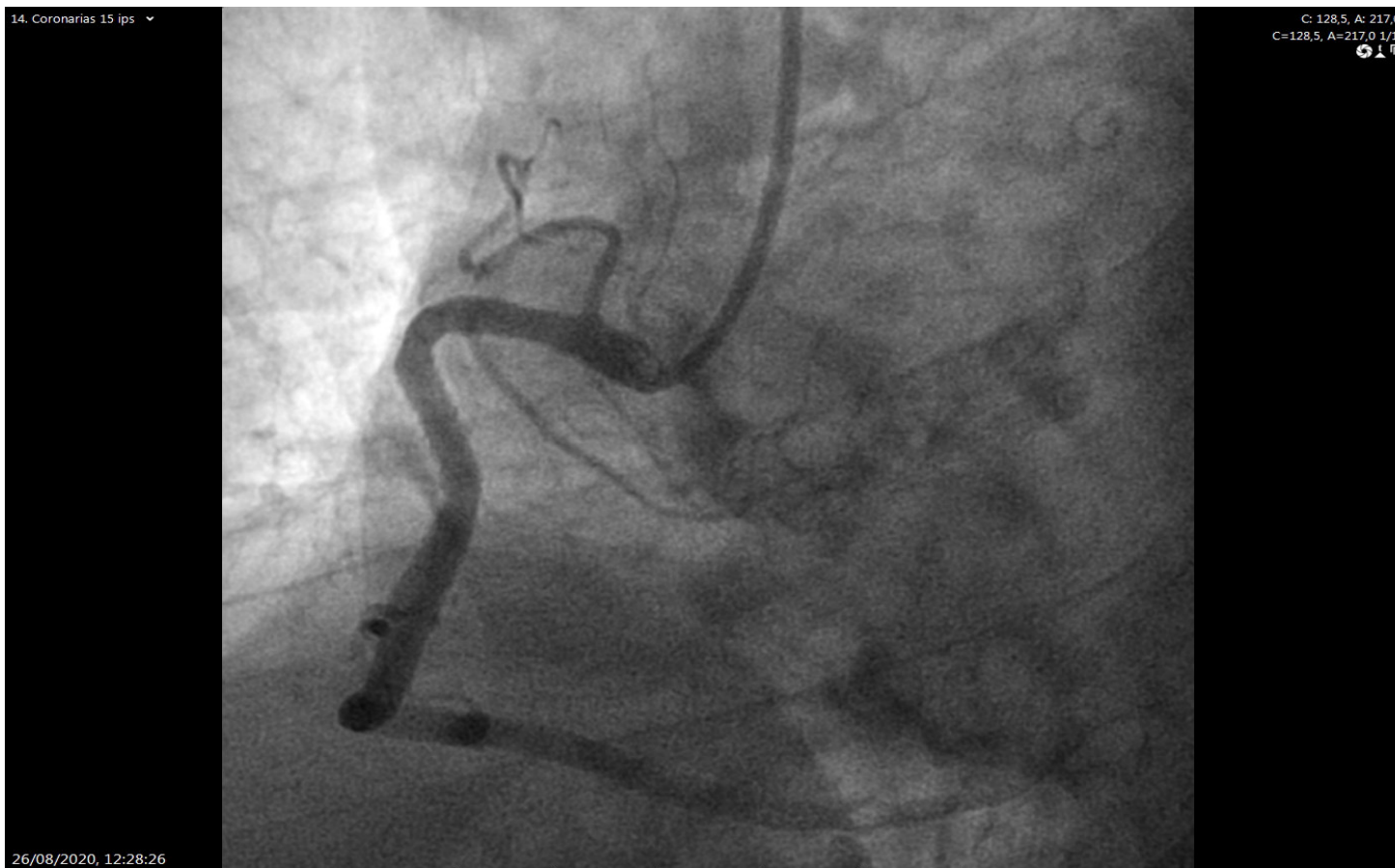
86 AÑOS

SCASEST CON ALTERACIONES EN EL ECG EN CARA INFERIOR

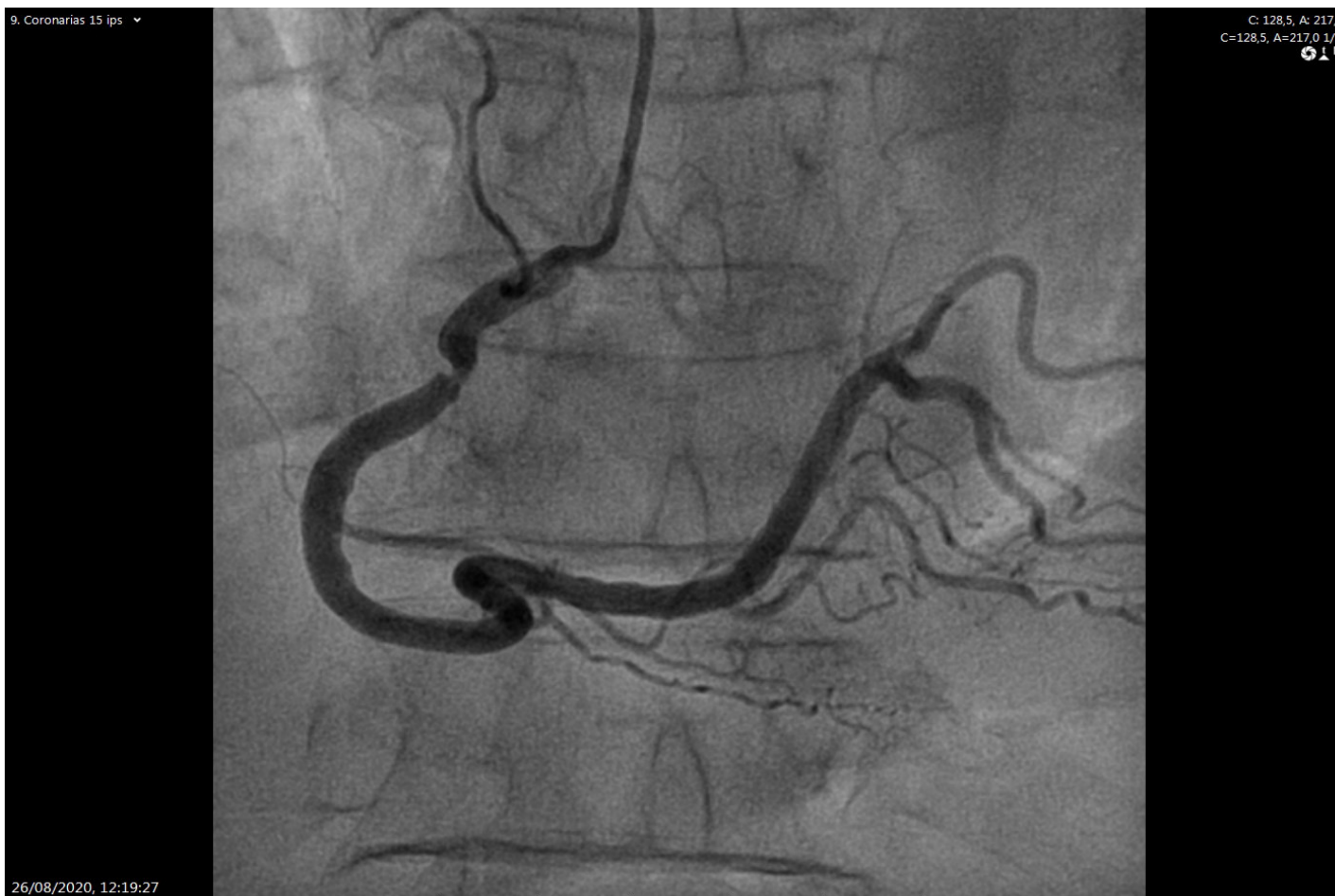ENFERMEDAD CORONARIA MONOVASO

SE DECIDE TRATAR CD MEDIA 75%

RESULTADO FINAL



PLACA COMPLICADA EN CD MEDIA



STENT BIOFREEDOM 4 X 14

